

Unexplained Abdominal Pain in Pregnancy and the use of the Term “Round

Ligament Pain”: A Single Centre New Zealand Pilot Cohort Study

Dr Hannah Louise Price, Dr Shannon Halpin, Dr Hashilah Husaimee Ahmad, Dr Emily Katherine Twidale: Obstetrics Department, Waikato Hospital, Te Whatu Ora, Hamilton, New Zealand, 3200



Introduction

Unexplained abdominal pain (UAP) in pregnancy is common, can be severe/ prolonged and can provoke iatrogenic preterm delivery. Anecdotally, round ligament pain (RLP) is a suggested diagnosis for UAP in pregnancy (1), however, we have found no scientific reference for the so-called condition.

Anterior Cutaneous Nerve Entrapment Syndrome (ACNES) is easily diagnosed and treated (2). It is thought to account for 10% of chronic abdominal pain in outpatients (3). The nerves perforate the abdominal wall fascia to provide cutaneous sensation to the abdomen (See figure 1). Irritation/entrapment causes a typical type of pain (4).

The diagnostic features of ACNES are severe abdominal pain of a stabbing/burning nature that is aggravated by physical activity and is always in the same location. On examination, patients have increased pain upon tensing the abdominal muscles. They also often have hypo/hyeraesthesia, dysaesthesia to ice and a positive **pinch** test (4).

A point of care transabdominal plane (**TAP**) block with local anaesthetic offers an immediate diagnosis and often long-term treatment (4).

The growing gravid uterus displaces the abdominal wall anteriorly, putting pregnant people at risk of ACNES (4).

Could we be falsely labelling ACNES in pregnant patients as Round Ligament Pain? Are we missing diagnostic and therapeutic opportunities?

Objectives

- ❖ To demonstrate that UAP is common and that without evidence medical carers continue to cite RLP.
- ❖ To show that pregnant people with UAP frequently use ACNES descriptors

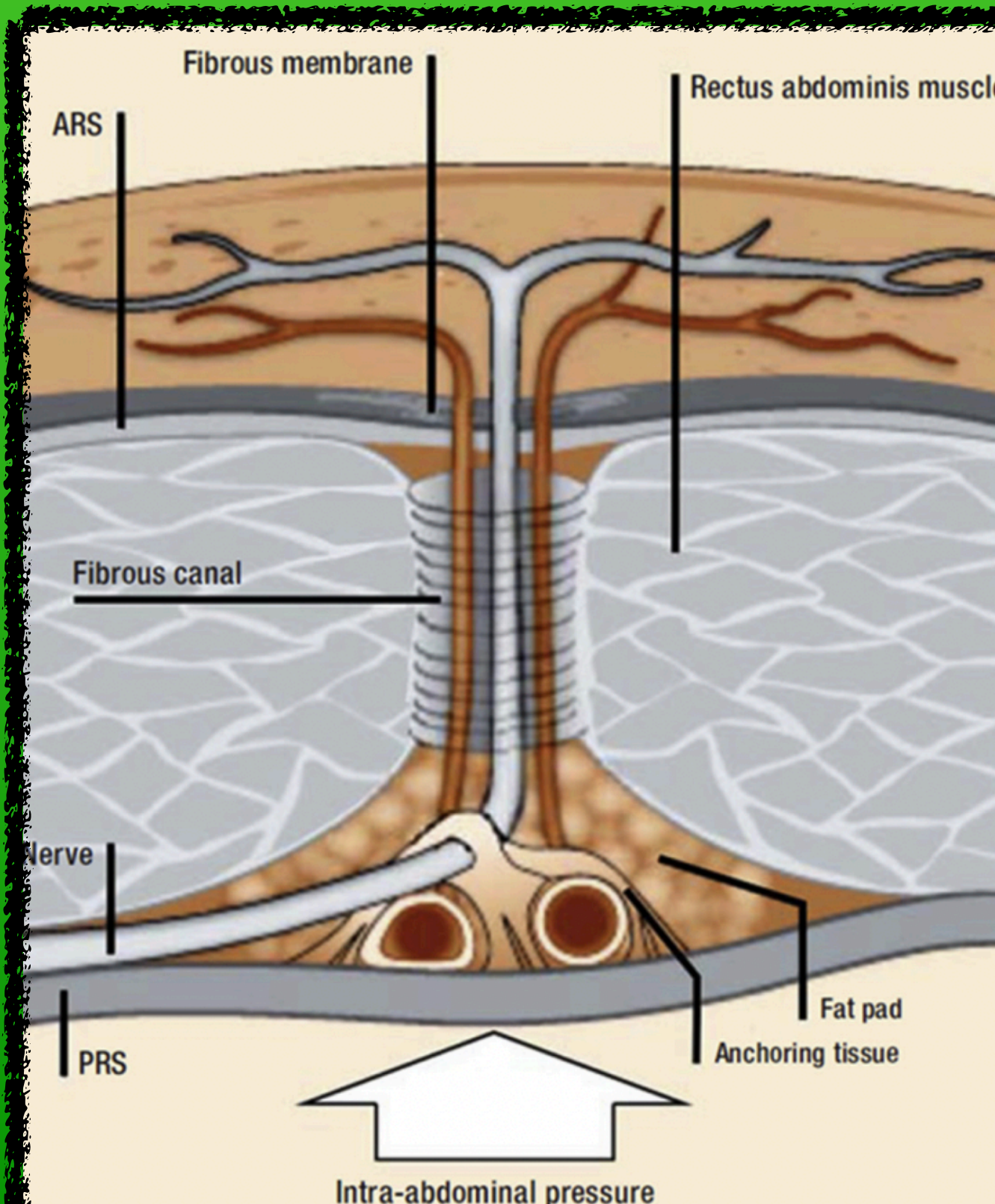


FIGURE 1. Double right-angle nerve course in anterior abdominal wall at edge of rectus abdominis muscle. ARS = anterior rectus sheath; PRS = posterior rectus sheath. From *Surg Gynecol Obstet.*¹⁴

Methodology

A prospective observational pilot cohort study of an antenatal clinic in NZ. 203 patients > 20 weeks' gestation completed a written **questionnaire**. Data included the proportion of patients who reported UAP, recognised the term RLP, the source of their RLP information, and whether their UAP fit any of the 14 descriptors provided; 11 of which were suggestive of ACNES.

Results

- ❖ 69% of participants had UAP in pregnancy
- ❖ 54% of participants recognised the term RLP
- ❖ Participants with pain were more likely to report medical carers as their RLP information source than those without pain with an odds ratio of 9.23 (95% CI 3.5-24.4).
- ❖ 99% of those with UAP used descriptors shared by ACNES
- ❖ Commonest ACNES descriptor was pain that was “ worsened by walking/bending/moving to sit” - 57% of participants

Discussion and Conclusion

UAP in pregnancy is common and our participants report that medical carers continue to cite RLP. 99% of our participants used descriptors for ACNES. We believe that this is the first attempt to propose an anatomically rational explanation for what is currently labelled RLP. The value of this finding lies in the therapeutic potential for these patients.

References

- (1) Nair, U. Acute abdomen and abdominal pain in pregnancy. *Curr Obstet Gynaecol Rep* 2005; 15(6): 359-367. (2) Kamboj AK, Hoversten P, Oxentenko AS. Chronic Abdominal Wall Pain: A Common Yet Overlooked Etiology of Chronic Abdominal Pain. *Mayo Clin Proc* 2019 Jan;94(1):139-144. (3) Srinivasan R, Greenbaum DS. Chronic abdominal wall pain: a frequently overlooked problem. Practical approach to diagnosis and management. *Am J Gastroenterol* 2002; 97(4):824-830. (4) Mol FMU, Maatman RC, De Joode LEGH, Van Eerten P, Scheltinga MR, Roumen R. Characteristics of 1116 Consecutive Patients Diagnosed With Anterior Cutaneous Nerve Entrapment Syndrome (ACNES). *Ann Surg.* 2021 Feb 1;273(2):373-378.