

Perineal Fibroadenoma Masquerading as Sarcoma: A Case Report

Authors: Wende G^{*1}, Cohen R², Chetrit S²

¹ King Edward Memorial Hospital for Women Perth, Subiaco, Western Australia, Australia

² St John of God, Mount Lawley Hospital, Western Australia, Australia



Background

- Ectopic breast tissue occurs in ~5% female population¹
- Usually appears along the milk line, near the mammary glands, but rarely it occurs inferior to the inguinal region¹⁻³
- In those with ectopic breast tissue, there is a higher incidence of urinary tract abnormalities e.g. polycystic kidneys, ureteric obstruction¹
- There are **less than 50 cases of vulval ectopic breast tissue** published in the literature.¹⁻³
- We describe a case of perineal fibroadenoma **masquerading** as a **soft tissue sarcoma** in a 35-year-old female.

Case

- **35-year-old female Gravida 0, Para 0**, presented with a two-year history of progressively **enlarging painless lump** in the perineal region.
- On examination there was a mobile, soft, non-fluctuant, non-tender mass located in the right perineum.
- Further workup with ultrasound and subsequent MRI demonstrated a 36 x 28 x 23 mm mass, separate to the anus, vagina and urethra, suspicious for soft-tissue sarcoma.
- The patient was advised to undergo punch biopsy followed by definitive management.
- However, she declined and instead opted for wide local excision, which proceeded without complication.
- Histopathology demonstrated a **fibroadenoma, mammary-type**, surrounded by pseudo-capsule, with **no atypia or malignancy** seen.

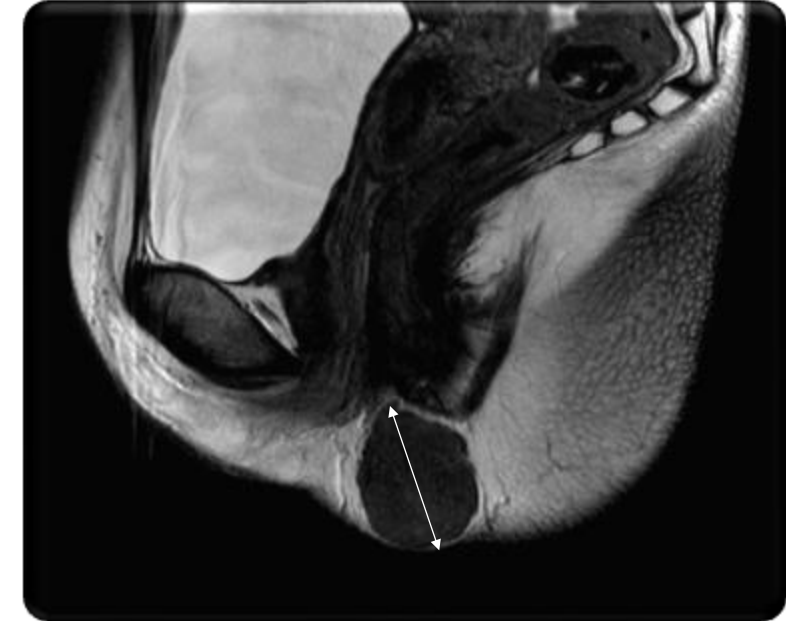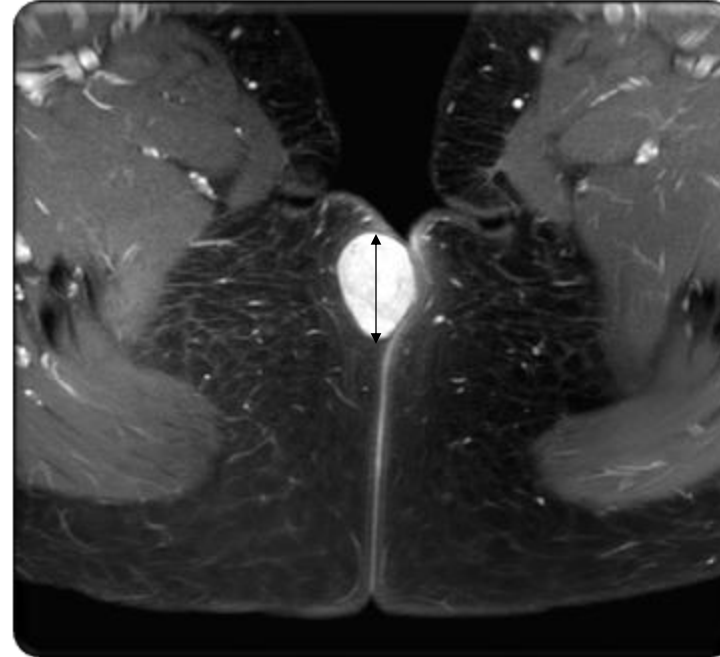


Figure 1 and 2 depict magnetic resonance imaging of the perineal mass.

Take Home Messages

- Vulval ectopic breast tissue is usually characterized as a painless, enlarging, soft tissue mass
- Fibroadenoma is an important differential to consider for perineal, vulva and perianal masses, as previous case reports have demonstrated fibroadenoma harbouring ductal carcinoma in-situ.
- The prognosis of ectopic breast carcinoma is poorer than normal breast malignancy, given earlier nodal involvement
- Patients with ectopic breast tissue should also have imaging to exclude urinary tract malformations

References

1. Li G, Zhang Y, Ma H. Recurrent vulvar breast fibroadenoma: presentation of a rare clinical condition. J. Int. Med. Res. 2019 47(3):1401-1405. Available from: doi.org/10.1177/0300060519826771
2. Duvvur, S, Sotres, M, Lingam, K. Ectopic breast tissue of the vulva. J Obstet Gynaecol 2007; 27: 530-531.
3. Deb, P, Swarup, D, Mishra, GC. Fibroadenoma of aberrant breast tissue in the vulva. Med J Armed Forces India 2000; 56: 153-154.