

# An outline of first generation endometrial ablation: Hysteroscopic Transcervical Resection of the Endometrium and Rollerball technique

Author: 1. Dr Brett Marshall MBBS, FRANZCOG

1. Consultant Gynaecologist, Royal Women's Hospital, Melbourne, Contact: [Brett@bdmarshall.com.au](mailto:Brett@bdmarshall.com.au) Conflict of interests: Nil

## Introduction ( Abstract)

Heavy Menstrual Bleeding (HMB) is a common condition affecting almost one in four women. (1) It is well established that it is a serious health condition that has negative effects on a woman's life. If medical management fails or is not appropriate, surgical management is the next treatment option. One such option in women who have completed their families is Endometrial Ablation (EA). This can be performed using a number of techniques often classed by their generation. One subset of first generation (1st gen) techniques is transcervical resection of the endometrium followed by rollerball (TCRE+R). It involves complete resection of the endometrium (and any focal pathology such as fibroids) using a hysteroscopic resectoscope cutting loop followed by diathermy of the basal layer with a rollerball coagulating electrode. The use of 1st gen EA techniques has decreased over the past decade in Australia as second generation (2nd gen) techniques are adopted. Whilst 2nd gen techniques require less surgical training, hysteroscopic resection followed by rollerball technique has many advantages including enabling direct visualisation, the ability to concurrently resect fibroids, not limited by cavity size/shape and other technical difficulties of the 2nd gen techniques and less environmental impact/equipment cost. This presentation outlines the indications, pre-operative preparation, surgical technique and peri-operative considerations for TCRE+R. Research often compares the success of first versus second gen techniques, however there is a paucity of literature outlining the exact surgical methods utilised in the various 1st gen EA techniques, often not clearly distinguishing between methods. The author proposes that comparisons should be between endometrial resection and non-resectoscopic endometrial thermal ablation (NREA) techniques to correctly compare results. In thoroughly outlining one first generation technique, gynaecological surgeons may be better guided in their future clinical practice.

**Objective:** To outline the indications, pre-operative preparation, surgical technique and peri-operative considerations for Transcervical Resection of the Endometrium and Rollerball (TCRE+R), a form of first generation endometrial ablation

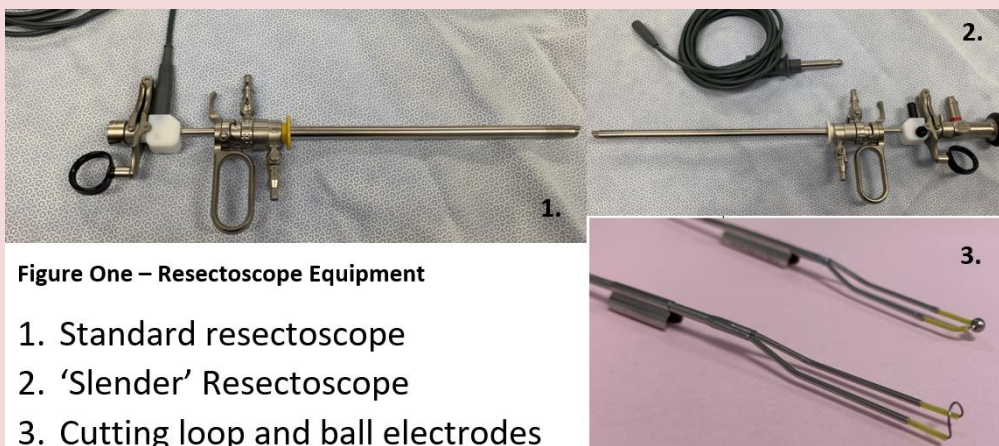


Figure One – Resectoscope Equipment

1. Standard resectoscope
2. 'Slender' resectoscope
3. Cutting loop and ball electrodes

## Methods

### Equipment

Storz operating resectoscopes were used with two different diameter options. The standard resectoscope setup uses a 26 F (9mm) operating sheath with 4 mm telescope, or the "slender" resectoscope of 21 F (7mm) sheath with 2.9 mm telescope. This thinner resectoscope can be used for the nulliparous or stenosed cervix. The working elements are a cutting loop for the resection and 3 mm rollerball coagulating electrode for the desiccation and haemostasis. A dual outer sheath/ dual port system and fixed (non-rotating) is preferred. Monopolar resection uses a blend setting with a cutting current of 100 watts and coagulation current of 50 watts. For rollerball ablation a coagulation current of 80 watts is used.

### Fluid

The fluid distending medium used is Glycine 1.5% and fluid delivery is via a gravity feed system with the Glycine bags placed at 100 cms above the patient. There are advantages and disadvantages to various irrigation fluids however Glycine 1.5% gives better visualization because it is less miscible with blood and non-conductive, whereas saline may have the advantage of reducing electrolyte imbalances. However both types of fluid can result in complications and can lead to fluid overload.

### Pre-operative Preparation

#### Endometrial Preparation

Pharmacologic thinning of the endometrium with pre-operative use of Danazol or GnRH agonists has been shown to result in a significantly thinner endometrium, improved visualization and operative conditions and reduced fluid absorption. (2,3) Danazol 200 mg t.d.s. was originally given for 5-6 weeks. This has now been reduced down to 2 weeks to still achieve adequate atrophy. Side effects have therefore decreased to only 2% of patients. Progesterone is best avoided as this can decidualize the endometrium.

### Cervical Preparation

Use of Misoprostol has been shown to soften the cervix and help with dilatation but has the risk of causing over-dilatation and loosening of the cervix, which results in loss of adequate intrauterine pressure and therefore visualization, and operative difficulties, with possible increased risk of complications. Misoprostol also causes significant side effects (4). No cervical preparation is used by the author. If the cervix is stenosed or the patient is nulliparous, the smaller "slender" operative hysteroscope can be used (7mm sheath). Another concern with Misoprostol causing increased laxity of the cervix, is that this may be a mechanism for thermal burns via capacitive coupling if the cervix does not have a tight fit to the equipment.

### Entry Technique

Cervical lacerations and uterine perforations are largely related to entry technique (5). Therefore straight Hegar dilators should always be used as they give the operator a much better haptic feedback compared with graduated dilators. The dilation of the cervix should be slow and gradual and the dilator should be left in situ until immediately before the next dilator is inserted. If the cervix appears small or fragile, it should be supported adequately with two vulsellae.

### Intra-Operative Technique

- Bipolar technology v Monopolar technology

There appears to be no statistically significant difference in complication rates between monopolar or bipolar technology however bipolar technology may cause more cases of excessive bleeding or fluid overload (Bahar et al.)

- Visualization is the key.

Therefore endometrial chippings should be removed with each resection pass.

- To avoid injury it is important to keep the resectoscope loop in view at all times and activate the loop only when moving it towards the operator.
- Care should be taken to ensure complete resection of difficult areas such as the fundal endometrium and cornual areas. If a history of caesarean section, then careful resection of the isthmic area to remove any caesarean section scar niche is important to prevent future abnormal bleeding.
- At the end of resection, the rollerball is used to achieve deeper endomyometrial ablation and achieve haemostasis.

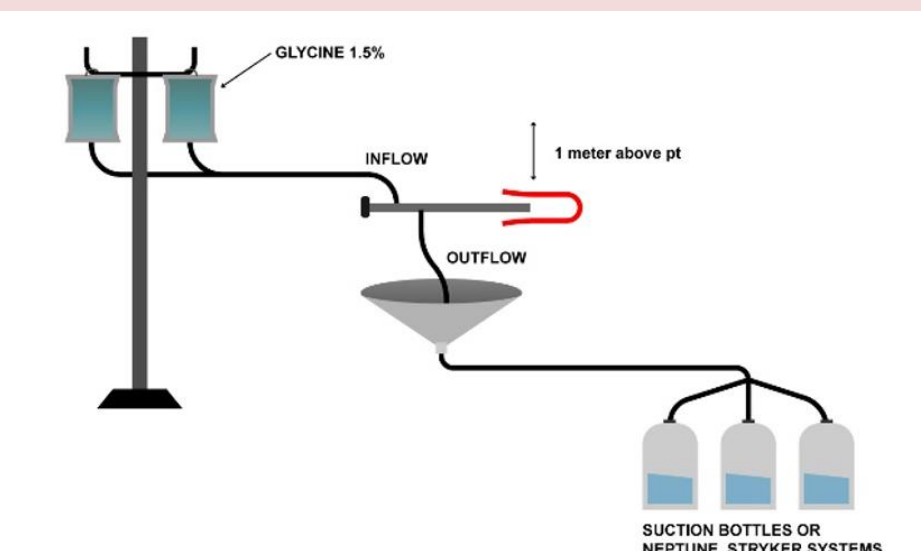


Figure Two – Diagram showing fluid set-up

### Fluid Monitoring

- Maintain the lowest intrauterine pressure necessary to provide clear visualization.
- Fluid absorption usually occurs when the intrauterine pressure is greater than the mean arterial pressure which is approximately 100cm H<sub>2</sub>O (6). Intrauterine pressure is kept at this level by placing the fluid bag at 100 cm above the patient, on gravity feed.
- The pressure delivered to the inflow port of the hysteroscope's outer sheath is a product of the elevation of the fluid bag and also the inner diameter of the connective tubing (7). An internal diameter of 4.75 mm (Baxter Y irrigation set) has been found to be ideal.
- The assessment of fluid volume inflow, compared with outflow, is extremely important and there should be a dedicated theatre staff member reporting the fluid deficit at 15 minute intervals.
- The procedure should be halted if preset fluid deficit thresholds are reached – pause at 750 mls, halt at 1000 mls – assess accuracy of fluid deficit and evaluate patient for possible fluid-related complications.
- For the fluid collection system, the outflow tubing from the operative hysteroscope flows into the large TURP style pouch drape (3M 1081) with suction tubing attached to the outflow of the pouch. This significantly reduces loss of fluid to other areas, thus improving accuracy of fluid collection and allows continuous monitoring of inflow and outflow via the suction canisters or a collection system such as the Neptune Fluid Management System (Stryker).
- Utilizing correct technique and monitoring of fluid results in an extremely low risk of fluid overload of 0.06 – 0.2 % (5,8). In our data the rate is 0.1%.
- No automated fluid management systems were used as in the author's opinion these create extra complexity and possible complications. These systems are expensive and studies report technical difficulties and no strong evidence in reduction of fluid overload risk (5). Furthermore, there have been recent reports to the TGA of serious morbidity with one of these systems.

### Post operative Management

If excessive bleeding:

- Use of small rollerball for specific dry burn to bleeding points and to achieve haemostasis.
- 30 ml balloon Foley catheter inflated within uterine cavity for tamponade with removal after 4 hours.

If fluid overload:

- Diuretic (IV frusemide)
- Assess and monitor electrolytes
- Be aware of risk factors or high risk patients.

Risk Factors:

- Long operative time (> 1 hr)
- Large glycine deficit (> 1000 mls)
- Intracavity pathology size and depth
- High intrauterine fluid pressures
- Medical co-morbidities – cardiac/ renal disease.

### Operator Skills – Training.

In comparing this 1st generation technique of TCRE + R with the newer 2nd generation thermal ablative techniques, many articles suggest that less technical skills are required for 2nd gen methods. However all methods can cause serious harm and there are potential disadvantages to stressing how little operator skill is required for 2nd gen devices which have the capacity to cause extensive intra-abdominal trauma, laparotomy and death.

### Advantages of TCRE + R

- Direct visualization.
- Full histological specimen obtained.
- Safety when there is myometrial thinning following past uterine surgery.
- Treatment of intra-cavity pathology/ fibroids (9).

Up to 20% of premenopausal women with HMB may harbor a polyp or myoma (10). Cavity distorting submucosal myomas require hysteroscopic resection because they may impact the safe placement of 2nd gen devices.

- Adenomyosis

Because endomyometrial resection can destroy the endomyometrium to a deeper level, it may lead to better outcomes when adenomyosis is present (11).

- Cavity size/ Uterine Anatomy

Compared with NREA methods, TCRE + R is not limited by cavity size/shape/anteflexion, uterine anomalies, or caesarean scar defects.

### Duration of surgery

The average operative time for TCRE + R endometrial ablation is 18 minutes (30 year audit, 1000 patients – E-poster, RANZCOG Oct 2019). The mean operative time for 2nd Generation EA methods is 14 minutes (12). However 2nd gen methods have a higher incidence of postoperative pain and nausea/ vomiting (12), therefore total theatre time may be equivalent.

## Conclusion

Hysteroscopic transcervical resection of endometrium followed by rollerball (TCRE + R) technique has many advantages compared with 2nd generation techniques. Limitations of 2nd gen devices may prevent general application to the HMB population. Thus not all women with HMB may be candidates for 2nd gen ablation methods and it has been suggested that gynaecologists should retain their skills in hysteroscopic resection surgery (13).

**References:** 1. Australian Commission on Safety and Quality in Healthcare. Heavy menstrual bleeding clinical care standard. Sydney ACSQHC; 2017. 2. Tan, Y and Lethaby A. Preoperative thinning agents before endometrial destruction for heavy menstrual bleeding. Cochrane database of systematic reviews 2013 (11). 3. Sharp H T, Obst Gynaecol 2006; 108 (4) 990-4. Crane J M, Journal of O & G Canada 2006; 28: 373 – 379. 5. Jansen FW et al. Complications of hysteroscopy: A prospective multicenter study. Obstet Gynaecol 2000; 96: 266. 6. Garry, R et al. The effect of pressure on fluid absorption during endometrial ablation. J Gynaecol. Surg 1992; 8: 1-17. AAGL Practice Report: Practice Guidelines for the Management of Hysteroscopic Distending Media, JMIG Vol 20, No 2, March-April 2013. 8. Aydeniz B et al. Multicentre survey of complications associated with 21,676 operative hysteroscopies. Eur. J Obstet & Gynaecol & Reprod Biol 2002; 104:1609. Bofill Rodriguez M et al. Endometrial resection and ablation techniques for heavy menstrual bleeding. Cochrane database of systematic reviews 2019; 10. Breitkopf DM et al. Obstet Gynaecol 2004; 104: 120-125 11. Zhou et al. Fertility & Sterility, 2011; 112. Lethaby et al. Endometrial resection and ablation techniques for heavy menstrual bleeding. Cochrane database of systematic reviews 2013 (8); CD 001501.13. Papadopoulos NP, Magos A. First generation endometrial ablation: Rollerball versus loop versus laser. Best Practice and Research Clinical Obstetrics and Gynaecology 2007; 21(6): 915-29.