

# Management of fallopian tube stump interstitial ectopic pregnancy: A case report

Sophie Doherty MBBS, Arifa Khan MBBS FRACGP FRANZCOG

**Key words:** *Interstitial, ectopic, methotrexate, cornual*

Dr Sophie Doherty, Department of Women's and Newborn Health, Westmead Hospital, Cnr Hawkesbury Road and Darcy Road, Westmead NSW 2145, Australia, [sophie.doherty@health.nsw.gov.au](mailto:sophie.doherty@health.nsw.gov.au) (Corresponding author)

Dr Arifa Khan, Visiting Medical Officer, Department of Women's and Newborn Health, Westmead Hospital, Cnr Hawkesbury Road and Darcy Road, Westmead NSW 2145, Australia [arifa.khan@health.nsw.gov.au](mailto:arifa.khan@health.nsw.gov.au)

## Abstract

Pregnancies implanted in the proximal segment of the fallopian tube embedded within the musculature of the uterus are known as interstitial ectopic pregnancies, these are very uncommon. Ipsilateral salpingectomy is a specific risk factor for interstitial ectopic pregnancies and there are a number of documented cases with a range of suggested treatments options. This is a case of a 34 year old Caucasian woman with a history of one emergency caesarean section and one previous ruptured right tubal ectopic pregnancy requiring salpingectomy, who presented with a ruptured stump ectopic pregnancy. A laparoscopy was performed and products removed from the pouch of Douglas, and applied diathermy to the bleeding cornua for haemostasis, the patient was stable and initially her serum HCG fell. On subsequent follow up testing however her HCG began to rise once again, she was treated with single dose methotrexate (MTX) at this institution. She was readmitted day 4 for a further rise in HCG and diagnosed with an ongoing interstitial ectopic pregnancy. This was treated with ultrasound guided injection of methotrexate in to the ectopic, after this her HCG was still not falling appropriately therefore a further dose of systemic MTX was administered. She then had an appropriate fall in HCG on follow up and remained stable.

## Introduction

Interstitial pregnancies account for 2-3% of all ectopic pregnancies<sup>1</sup>, and as such make up only a small portion of cases. As a note, the terms cornual and interstitial ectopic pregnancies are often used interchangeably in the literature and in clinical documentation, however in much of the literature and in some clinical guidelines<sup>2</sup>, cornual pregnancies are referred to as those pregnancies found in the rudimentary horn of a unicornuate uterus. For the purposes of this case I refer specifically to an ectopic pregnancy located in the most proximal portion of the fallopian tube. Interstitial ectopic pregnancies can be life threatening<sup>3</sup> and carries a mortality rate of 2-2.5%<sup>4</sup>. There is insufficient evidence to support systemic versus local injection of MTX, and there are no high quality studies comparing single versus multi-dose regimens when using MTX<sup>5</sup>.

I present a case of a woman with an interstitial ectopic pregnancy, who underwent laparoscopy, and both systemic and local methotrexate therapy, in this case it was only after her second systemic dose of MTX that her beta-HCG appropriately fell.

## Case Presentation

A 33 year old gravida 3 para 1 woman with a history of right salpingectomy for a tubal ectopic presented to a private hospital with abdominal pain and a beta HCG of 19759, at 6 weeks and 2 days gestation, pelvic ultrasound was performed suggesting a ruptured ectopic pregnancy and heterogenous free fluid in the pouch of Douglas consistent with haemoperitoneum. She underwent laparoscopy and 500mL of haemoperitoneum was found with what appeared to be products of conception in the pouch of Douglas, diathermy was applied to the bleeding right sided cornual stump. Histopathology confirmed the specimen as products of conception.

She was referred to our institutions' Early Pregnancy Assessment Clinic (EPAC) for MTX 4 days post operatively as her beta-HCG plateaued after initially falling at 13000. She received a systemic dose of MTX (50mg/m<sup>2</sup>) She subsequently presented to the emergency department on day 3 with abdominal pain similar in character to her initial rupture event however was stable and sent home with simple analgesia, with a plan to return the following day (Day 4) for her day 4 MTX bloods and beta-HCG. Concerningly, her HCG had risen to 15982 on Day 4, she was therefore admitted for monitoring and an ultrasound scan.

A tertiary ultrasound in the Westmead Institute for Maternal Fetal Medicine. This was reported as a residual cystic structure within the interstitial portion of the right cornua 15x12x12mm. There was no fetal pole or yolk sac seen, with prominent vascularity suggestive of a decidual reaction. Appearances were of interstitial ectopic pregnancy. The treatment decision was of local injection of MTX in to the residual interstitial pregnancy. Importantly, the patient and her husband expressed they did not want to compromise plans for more pregnancies, therefore a wedge-excision of the uterus to remove the remaining pregnancy was avoided., though considered.

After counselling, the patient was consented for an ultrasound guided direct injection of MTX in to the pregnancy as well as dilatation and suction curettage, which went ahead the same day. In the period post this procedure, three consecutive beta-HCG readings 48 hours apart were static. A further dose systemic methotrexate was administered to once again avoid a further surgical procedure, after this it steadily fell at an acceptable rate and she was clinically stable.

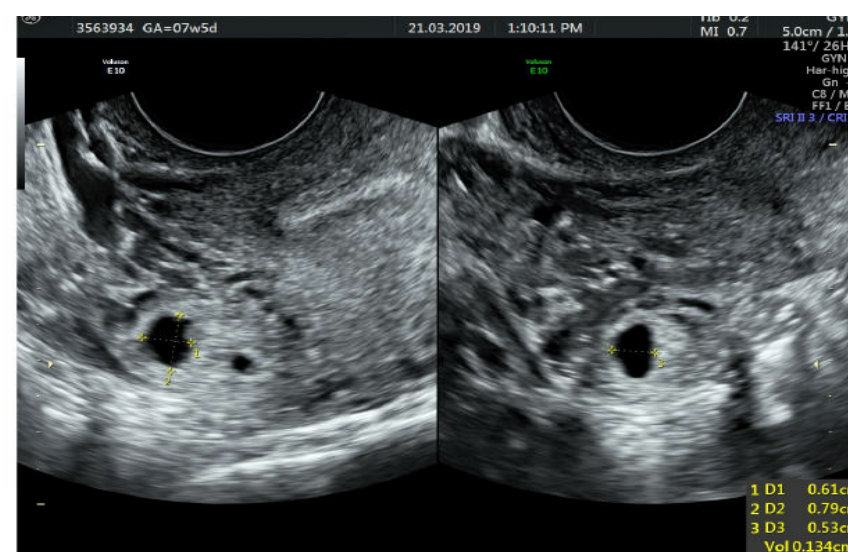


Figure 1  
Residual cystic structure within the interstitial portion of the right fallopian tube  
Echogenic rim and anechoic centre, no fetal pole or yolk sac

## Discussion

An ectopic pregnancy in the interstitial portion of the fallopian tube only makes up a tiny number of total ectopic pregnancies, 2-4%, therefore reported treatment regimens of both systemic and local methotrexate therapies vary and the evidence to support one over another is limited. Interstitial ectopic pregnancies carry a higher mortality rate than tubal ectopic pregnancies, the location makes for a more difficult diagnosis, and tends to rupture at more advanced gestations<sup>4</sup>. In a five-year audit at a tertiary institution in Australia, 11 cases of interstitial ectopic pregnancies were treated with a bolus and 12 hour infusion intravenous methotrexate therapy, they reported a success rate of 91% with their treatment regimen, with a mean initial beta-HCG count of 25292<sup>4</sup>.

An 11 year retrospective audit of non-tubal ectopic pregnancies at a different Australian tertiary hospital suggests that management with systemic and or ultrasound guided intra-sac injection of methotrexate are highly effective<sup>1</sup>. This study grouped 41 cornual-interstitial pregnancies in to one category and didn't identify how many within this category were treated with these methods vs surgical treatment. They did report a higher success rate when ultrasound guided intra-sac injection was used either alone or in combination with systemic therapy over systemic therapy alone in these cases, and suggest that use of ultrasound guided intra-sac injection of methotrexate either alone or in combination with systemic methotrexate should be a primary management option in the case of cornual-interstitial ectopic pregnancies<sup>1</sup>.

Our case is that of initial management with systemic methotrexate, followed by ultrasound guided intra-sac injection of methotrexate, with a further dose of systemic methotrexate required after this due to a plateauing beta-HCG. Guidelines surrounding best management for interstitial ectopic pregnancies refractory to initial management are unclear, and this case reminds clinicians that this group of ectopic pregnancies often carry a higher mortality rate due to the greater gestation at diagnosis, and perhaps require consideration of a different treatment regimen to more common tubal ectopic pregnancies.

## Contributors

Sophie Doherty MBBS and Arifa Khan MBBS FRACGP FRANZCOG were equal and sole contributors.

## Conflict of Interest

The authors declare that they have no conflict of interest.

## Funding

No funding was sought or secured in relation to this case report.

## Consent

Written informed consent was obtained from the patient for the publication of this case report

## References

1. Ramkrishna J, Kan GR, Reidy KL, Ang WC, Palma-Dias R. Comparison of management regimens following ultrasound diagnosis of nontubal ectopic pregnancies: a retrospective cohort study. *BJOG* 2018;125:567-575.
2. Elson CJ, Salim R, Potdar N, Chetty M, Ross JA, Kirk EJ on behalf of the Royal College of Obstetricians and Gynaecologists. Diagnosis and management of ectopic pregnancy. *BJOG* 2016; 123:e15-e55
3. Larraín D, Marengo F, Bourdel N, Jaffeux P, Aublet-Cuvelier B, Pouly JL, Mage G, Rabischong B. Proximal ectopic pregnancy: a descriptive general population-based study and results of different management options in 86 cases. *Fertil Steril*. 2011;95(3):867. Epub 2010 Nov 3
4. Tang A, Baartz D, Khoo SK. A medical management of interstitial ectopic pregnancy: A 5-year clinical study. *ANZJOG* 2006 46: 107-111
5. Tulandi T. Ectopic pregnancy: methotrexate therapy. UpToDate guidelines. Last updated 21 March 2018. Topic 5407 Version 29.0